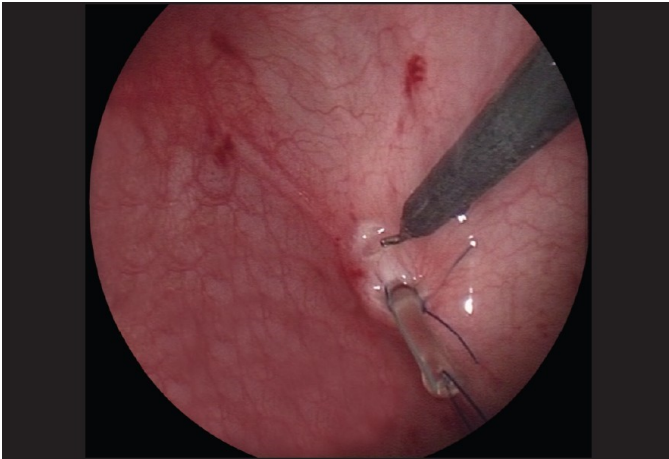


## Risks

- Blood loss 20-500cc
- May convert from a laparoscopic to open procedure.
- Wound Infection.
- Post-operative hernia formations especially associated in the elderly with atrophic abdominal muscles
- NB! Each person is unique and for this reason symptoms vary!



# Urologist



**Dr Jo Schoeman**  
Specialist Urologist

## PATIENT INFORMATION BROCHURE

## *RADICAL NEPHRO- URETERECTOMY*

See this live on:  
[vidscrip.com/urojo](https://vidscrip.com/urojo)

Patient well-being is my first priority!

**Jo Schoeman**  
FRACS, FCS (Urol) SA, MBChB

The Wesley Hospital  
Suite 10 Level 9  
Evan Thompson Building  
24 Chasely Street  
AUCHENFLOWER QLD 4066

Ph: 07)3371-7288  
Fax: 07) 3870-5350  
E-mail: [jo@urojo.com.au](mailto:jo@urojo.com.au)  
Emerg: 0403 044 072

[www.brisbane-urologist.com.au](http://www.brisbane-urologist.com.au)

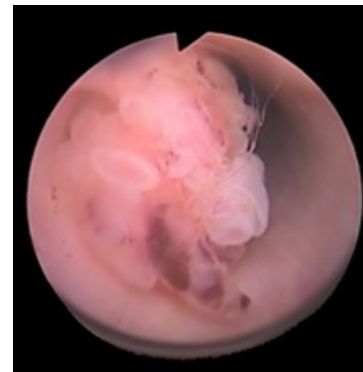
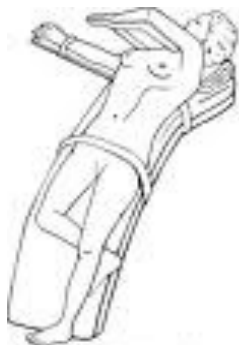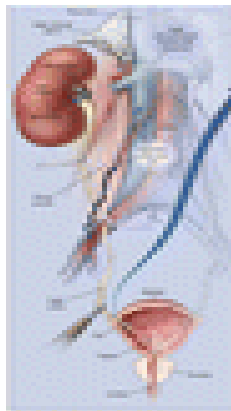
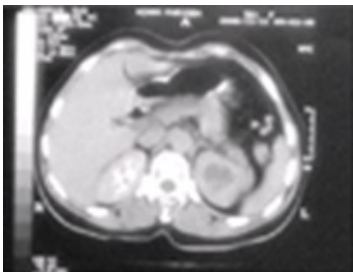
## Radical Nephro-ureterectomy

For urothelial cancers contained in the kidney/ureter. This is an intended curative procedure, depending on staging. It involves removing the complete reno-ureteric unit with a cuff of bladder.

It can be done open or laparoscopically

### Why is it done?

- Finding of 1 or more solid lesions within the collecting systems of the kidney or ureter (intraluminal)
- Usually presents with macroscopic hematuria and flank pain
- Usually a Urothelial Carcinoma (previous Transitional Cell Carcinoma TCC)
- Potentially curative process if staging is negative ie. No spread of tumour
- Staging with
  - CT abdomen and chest
  - Bonescan / FD PET
  - MRI if in Renal Failure or Contrast Allergy
- Could also be done in metastatic disease with uncontrollable hemorrhaging.



### How is it done?

- Patients will receive a general anaesthesia.
- Prophylactic anti-biotics is given.
- The correct kidney is identified and marked while you are awake
- A Cystoscopic loosening of the lower ureter in the bladder is done and tied off to prevent cancer cell spilling
- A cystoscopy will be done first with a loosening of ureter inside the bladder and tied off of the ureter in order that there will be no spilling of ureteric content in the abdomen
- Depending on the side of the tumour 3-4 incisions will be made:
  - 1 for the hand-port of approximately 8cm depending on the amount of sub-cutaneous fat present
  - 1 for the camera-port
  - 1 for the working-port
  - (1 for the liver retractor on the right)
- The colon is reflected to reveal the retro-peritoneal space
- The ureter is identified and cleared up to the hilum
- The arteries are identified and marked with vessel loops More than 1 can be present. Confirmed with CT arteriography
- Then the vein/veins are identified and marked with a vessel loop.
- The rest of the kidney is mobilized and loosened
- Then the ureter is mobilized all the way down into the pelvis and plucked from the bladder where it has been loosened
- Drain are left post-operatively.
- A catheter will be left for minimum of 5 days

### What next?

- You will spend up to 5 nights in hospital.
- You will have a catheter for that time.
- A drain for 2-3 days.
- You will a trial without the catheter on the 5th day
- Renal functions will be checked daily.
- You may enter a phase of poly-uria. High production of urine as the remaining kidney adjusts to the higher work-load.
- You may be discharged with a catheter for 10 days and removed on a subsequent visit
- You will be discharged as soon as your renal function has stabilised and you can function independantly..
- Allow for 6 weeks for stabilization of symptoms.
- Restrict fluid intake to less than 3 L per day.
- A ward prescription will be issued on your discharge, for your own collection at any pharmacy
- A follow-up appointment will be scheduled for 6 weeks. Remember there is no pathology due to vaporization.
- Don't hesitate to ask Jo if you have any queries
- **DON'T SUFFER IN SILENCE, OR YOU WILL SUFFER ALONE!**

### Very Important!!

The correct side for surgery should be checked :

- CT scan present
- Your approval
- Prior to anaesthesia being commenced